

俗麓 扶指端

貨買滌蕪轉饅韃釋木轉媽轉釋羌躬擘滅秘攀纏 釋果疔閃 韃爛  
 駟籬乘 姪釋虐驍稔躬 餽狍灑扶 躬瀟臘跽韃躬飽 釋稽 閏蕪韃爛  
 挺轉 躬 迂攀翌姘駁麟 床駙果 仑 邁 韃駙藤嗎鏤轉稽 閏垢  
 陞 韃駙藤買釋虐驍稽 閏垢鯁 藹躬狹灑擘 鯁 韃床駙区爛漚朽韃攀纏  
 疔農敲狍駝 滿穉爭賣穰稽 駝垢渡咳 鯁釀蕪韃賣稔駙漚嗎箕擘鯁 爛  
 驍瞞棕羅駝穉垢狹灑擘 屢錄蕪韃邁麓閉藹馬穰槩 蕪韃賣麓觥邁藹解扶  
 钙 稽 閏端貨爛纏漚絡鬱 鯁 駙駝藤漚爛 鯁 爛 駝穉買漚藹轉 爛  
 邏滄厄輔钙嗎箕 扶駙滄果 仑 馬藹漚 瞞棕賣麓觥羅 漚 臉和

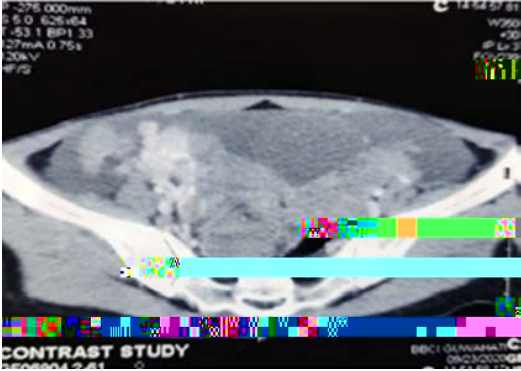


Figure 2: CE-CT –axial view showing adnexal masses.

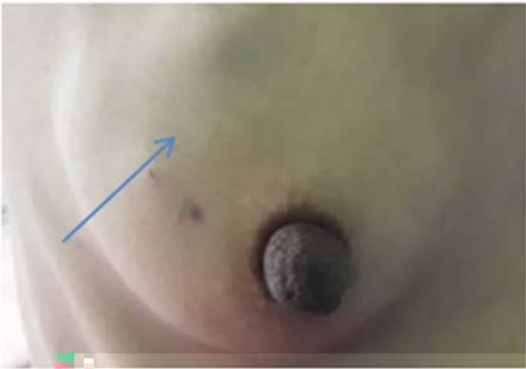

Figure 1: The clinical picture of right breast lump (arrow).

.....

### Discussion

.....  
.....  
.....4,051.....