

Periodontal Infrabony Defects

Song GM*

Department of Oral Diagnostic Sciences, University of Florida College of Dentistry, Gainesville FL 32606, USA

*Corresponding author: Song GM, School of Dentistry, University of Missouri-Kansas City, Missouri, USA, Tel: +1 816-235-100; E-mail: songg@dental.uf.edu

Received date: June 27, 2016, Accepted date: July 18, 2016, Published date: July 20, 2016

Copyright: © 2016 Song GM. This is an open-access article distributed under the terms of the Creative Commons Attribution License, which permits unrestricted use, distribution, and reproduction in any medium, provided the original author and source are credited.

Abstract

The key normal for ruinous periodontal ailment is the loss of tooth-supporting alveolar bone. In general, even bone misfortune is separated from vertical bone misfortune, which is termed as an infrabony deformity since the base is apical to the alveolar peak. The nearness of infrabony formities confuses minor periodontitis furthermore, impacts treatment and anticipation.

Consequently, the reason for this study was to decide the recurrence and area of interproximal infrabony imperfections (IPIDs) recorded from all-encompassing radiographs (PRs) of grown-up patients tested at the radiological chronicle of University, School of Dentistry. The impact of age, sex and remaining teeth on the nearness of IPIDs was additionally researched.

Keywords: Periodontal ailment; Infrabony; Ortopantomograph; Flatbed scanner; Gastronomical

Introduction

PRs were gotten utilizing Ortopantomograph OP-100 Palomex (OY-Finland and Siemens Corp-West Germany) what's more, the movies were produced in a programmed film processor. After digitization with a flatbed scanner at 600 dpi (Hewlett Packard Scanjet XPA 7400c), pictures were spared as TIFF documents what's more, moved into a product (UTHSCSA Image Tool Adaptation 3.0, San Antonio, Texas). The review sessions were performed in an obscured space to minimize glare with the pictures showed on a 17 inch screen [1,2].

Background

Background

Inward breath Conscious Sedation is otherwise called "Nitrous Oxide/Oxygen Sedation." Nitrous oxide, regularly and improperly called giggling gas, has been utilized by dental practitioners for almost 100 years. It is a phenomenal pain relieving) very quickly so there is no headache impact

Figure 1).




Figure 1: Inward breath conscious sedation.

Background

When you are perplexed, your edge for agony is much lower; you get to be excessively touchy to each sensation, prick, and clamor. Trepidation and uneasiness trigger the arrival of specific chemicals like adrenaline which put your "battle or fight" senses on high ready. You envision that something is going to hurt thus you strained your muscles, regardless of the fact that it is subliminally. In this elevated condition of uneasiness you encounter more torment amid and even after treatment. Notwithstanding this reaction can for all intents and purposes be wiped out with oral sedation dentistry!

The entire motivation behind oral sedation is to make you as agreeable and casual as would be prudent. It permits you to let your gatekeeper down, unwind both your brain and body, and concentrate on feeling quiet as opposed to on edge. Your trepidation and touchiness to torment dissolve away, yet you stay alert and in control (Figure 2).

X●

#E 312 N. fD88 ©A.Gb

BI,

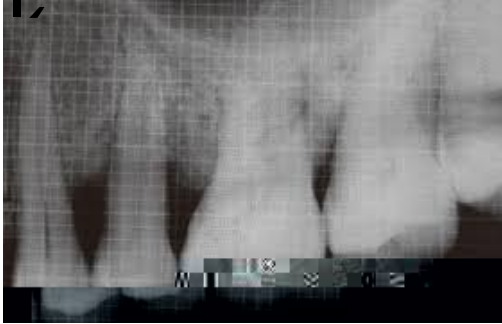

Figure 2 X-ray showing anxiety just melts away.

H|a Y|c di hXck b h YXf]`3

Lasers in numerous hard tissue dental applications (tooth finish, denture and bone) dispense the requirement for the dental dri] b b e Mi

